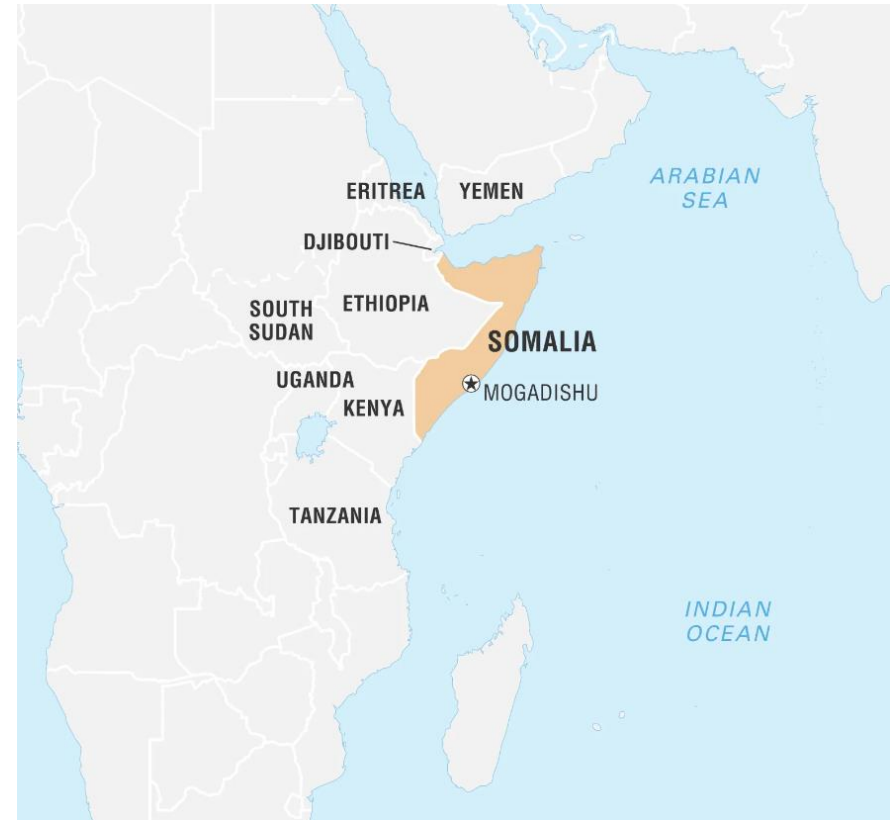

CASE PRESENTATION

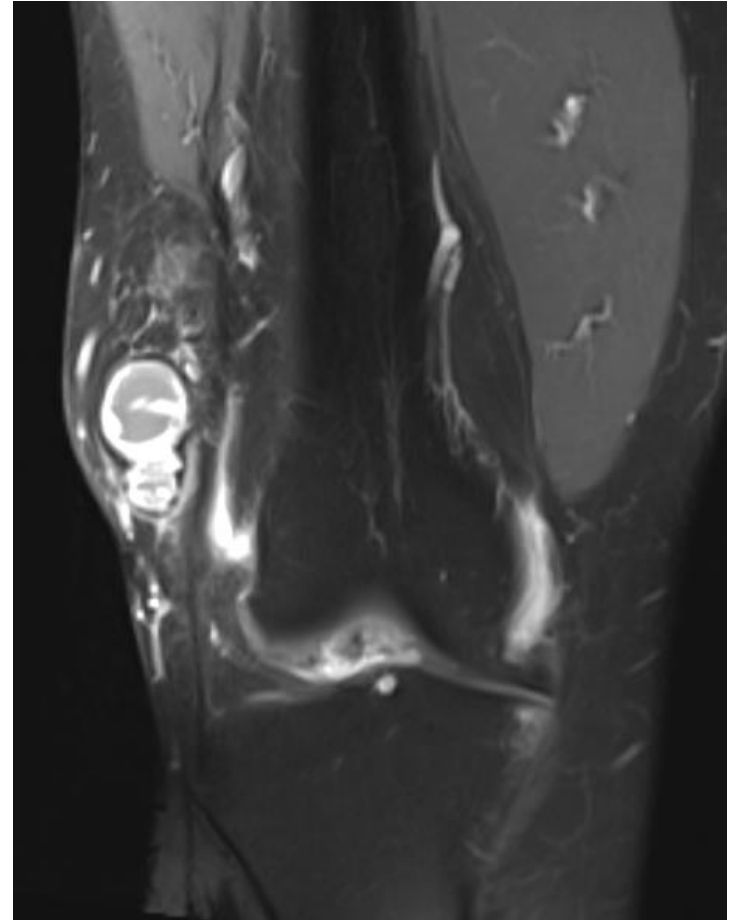
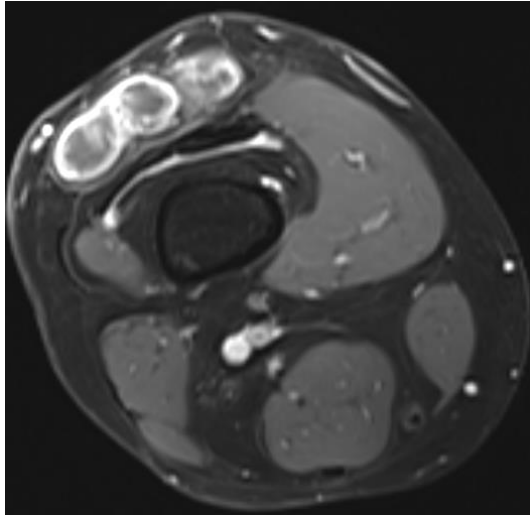
02.02.2023 Case presentation, Jeanne Bisch

Mr. W., H.; 62 years

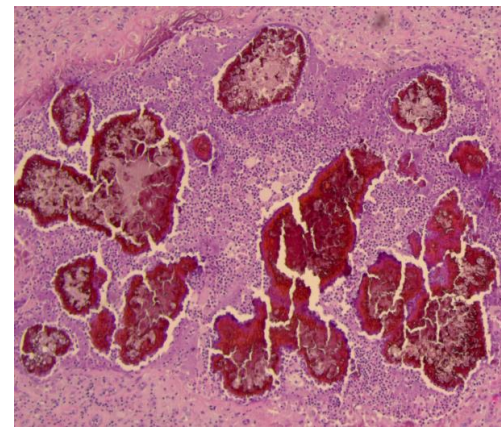
- from Somalia, since 2008 in CH with his family, facility service worker
- arterial hypertension
- amlodipin
- 01/22 presentation to primary care physician:
 - **Increasing swelling above the right knee** (since operation of the knee after an accident years ago in Langenthal?)



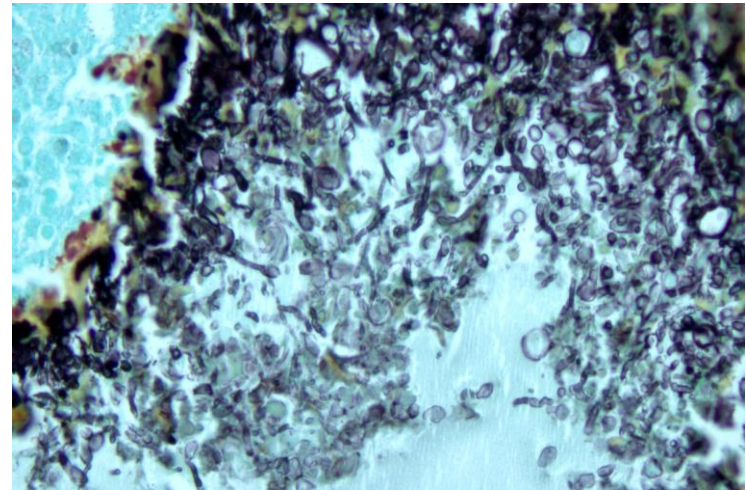
- 02/22 MRI right thigh:
 - in subcutis of the distal thigh **multiple small, round to oval-shaped hyperintense lesions surrounded by a small rim**; no infiltration of muscles or bones; size 6.5x6x2cm



- 02/22 Excision of lesion, intraoperative spillage:
 - cystic lesion containing purulent tissue with black grains
 - histopathology: by connective tissue encapsulated floride and granulomatous abscess with fungi
 - no tissue sent to microbiology

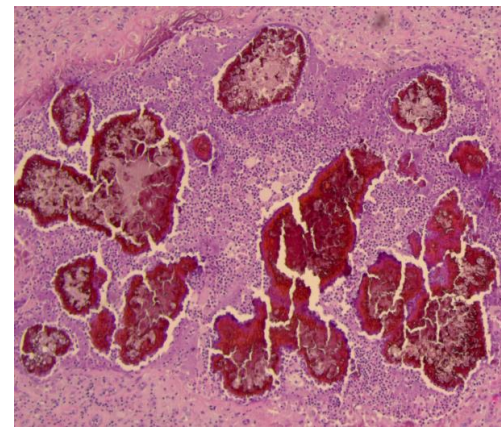


HE 50x

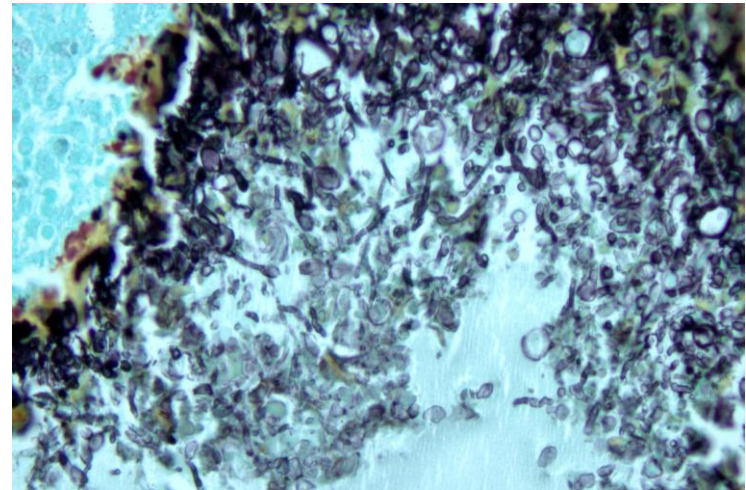


Grocott 400x

- 03/22 presentation to infectiology
Inselhospital Bern:
 - Scar without signs of inflammation
 - HIV, HTLV negativ
 - HbA1c 6.8% -> Diabetes mellitus
 - **Panfungal PCR** from excised tissue thigh:
Madurella species
 - Problem: no resistance testing available

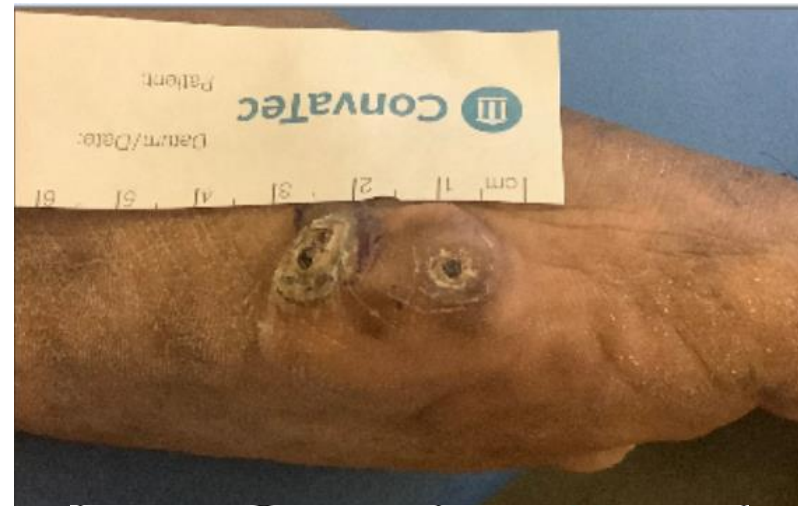

HE 50x



Grocott 400x

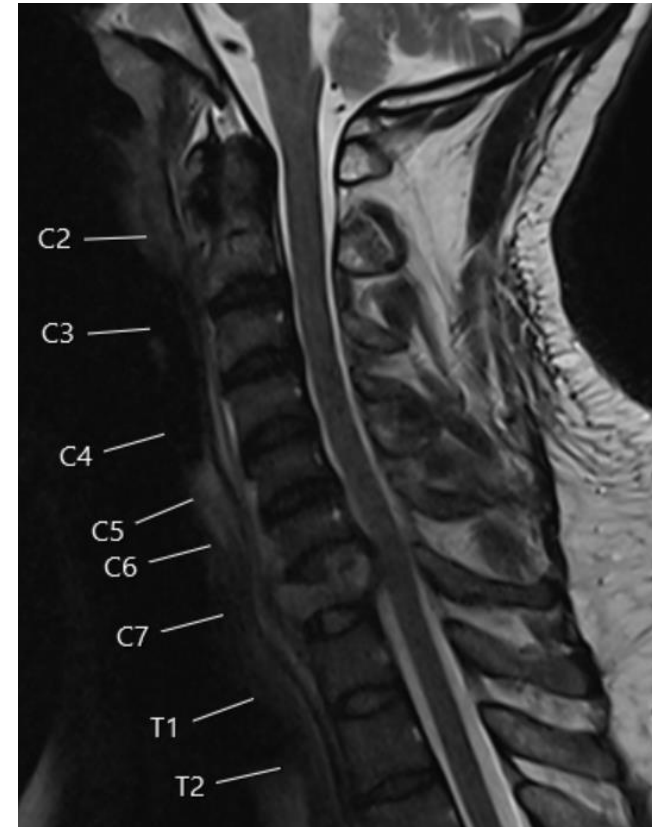
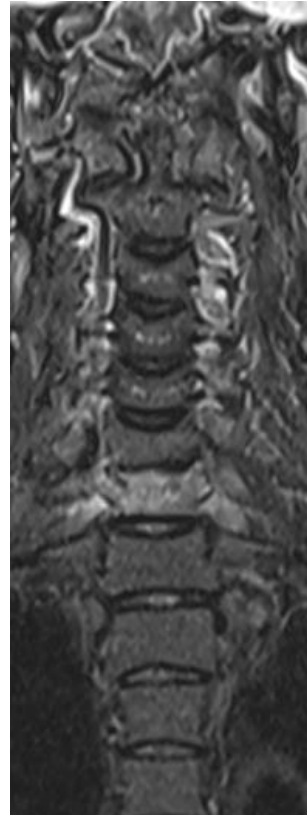
- 03/22 presentation to infectiology Inselspital Bern:
 - ... Lesion left medial foot
- 03/22 biopsy and 05/22 excision lesion left foot:
 - MRI: no infiltration of bones
 - histopathology: chronic active granulomatous inflammation with fungi
 - microbiology: **Fusarium solanii**



Amphotericin B	R
Itraconazol	R
Voriconazol	R
Posaconazol	R
Isavuconazol	R
Terbinafin	S
Anidulafungin	-
Caspofungin	-
Micafungin	-

- 08/22 Decision:
 - **Madurella**: empirical treatment with **Itraconazol**, duration 12 months
 - **Fusarium solanii**: no treatment necessary, because in toto resected

- 08/22 Presentation to emergency room:
 - right sided neck pain, weakness right arm and numbness Dig I/Dig II right hand
- MRI cervical spine:
 - **Pathologic fracture of 7th cervical vertebral body with infiltrative process** of soft tissue and bone marrow
- Operation cervical spine:
 - Histopathology/microbiology:
Mycobacterium tuberculosis



- **Treatment:**

- **Antituberculous «standard» treatment**
(2 months RIF, INH, PZA, (EMB) -> 7-10 months RIF, INH)
- No treatment for madurella at the moment because of interaction (reduced serum concentration of itraconazol)

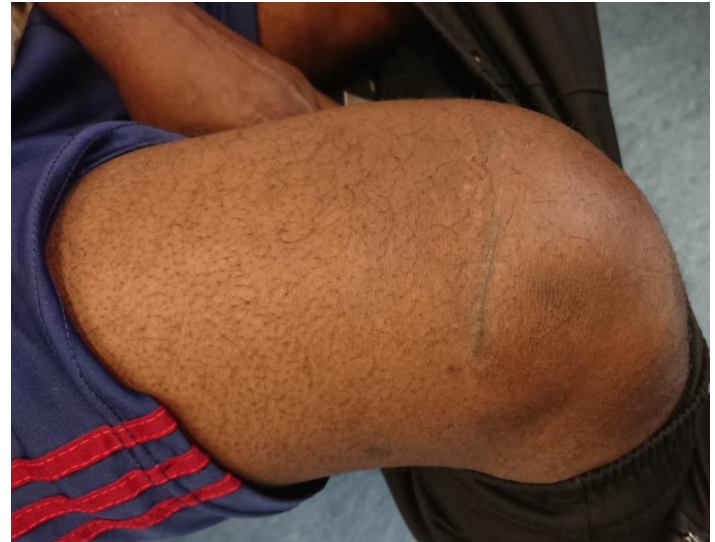- **Clinical course:**

- No side effects, neck pain resolved, no neurologic sequelae
- no clinical signs of inflammation of right knee and left foot, watchful waiting



Itraconazole
Rifampicin (INT) (CYP3A4 Inducers (Strong))

Risk Rating X: Avoid combination



THANK YOU FOR YOUR ATTENTION